

Mansfield Animal Clinic

1260 North Main Street, Mansfield Animal Clinic, TX, 76063

Phone: 817-473-1012

Fax: 817-473-1315

Email: admin@mansfieldanimalclinic.com

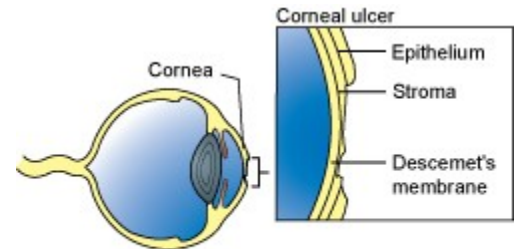
Website: www.mansfieldanimalclinic.com

Corneal Ulcers in Dogs

What is a corneal ulcer?

The *cornea* is the transparent, shiny membrane that makes up the front of the eyeball. Think of it as a clear windowpane. To understand a corneal ulcer, you must first know how the cornea is constructed.

There are three layers in the cornea, all of which are highly specialized skin cells. The outermost layer is the *epithelium*, which is a very thin layer of cells. Below the epithelium is the *stroma*, which is the main supportive tissue of the cornea, and the deepest layer is *Descemet's membrane*. Because all of these layers of the cornea are clear, it is not possible to see them without special stains that color specific cells and highlight them when the tissue is examined under a microscope.



Used Under License
Copyright © Lifelearn Inc.

Erosion of a few layers of the epithelium is called a *corneal erosion* or *corneal abrasion*. A *corneal ulcer* is deeper erosion through the entire epithelium and into the stroma. With a corneal ulcer, fluid is absorbed from the tears into the stroma, giving a cloudy appearance to the eye. If the erosion goes through the epithelium and stroma to the level of Descemet's membrane, a *descemetocoele* is formed. A descemetocoele is a very serious condition. If Descemet's membrane ruptures, the liquid inside the eyeball leaks out, the eye collapses and irreparable damage occurs.

How does a corneal ulcer occur?

There are several causes of corneal ulcers in dogs.

"The most common cause is *trauma*."

The most common cause is *trauma*. An ulcer may result from blunt trauma, such as a dog rubbing its eye on the carpet, or due to a laceration, such as a cat scratch or a contact with a sharp object. Another common cause is chemical burn of the cornea. This may happen when an irritating chemical or substance such as shampoo or drywall dust gets in the eye.

Less common causes of corneal ulcers include bacterial infections, viral infections, and other diseases. These may originate in the eye or may develop secondary to a disease elsewhere in the body. Examples of other diseases include:

- Epithelial Dystrophy - a weakening of the cornea which can be inherited in breeds such as the Boxer
- Drying of the cornea due to decreased tear production, called keratoconjunctivitis sicca (KCS or "dye eye")

- Endocrine diseases such as diabetes mellitus, Cushing's disease (hyperadrenocorticism), and hypothyroidism

How does a corneal ulcer affect my dog?

"Corneal ulcer is very painful."

A corneal ulcer is very painful. Most dogs rub the affected eye with a paw or on the carpet in an attempt to relieve this intense pain. To protect the eye, they keep the lids tightly closed. Occasionally, a discharge will collect in the corner of the eye or run down the face.

How is a corneal ulcer diagnosed?

Superficial corneal abrasions are generally not visible without special tests and equipment. Corneal ulcers are detected with the use of special stains such as *fluorescein*. A drop of this stain is placed on the cornea. The dye will turn green and adhere to areas of ulceration. Large ulcers are readily visible, while tiny ulcers may be enhanced by the use of special ophthalmic lights and filters. A fluorescein stain test is the most common eye test performed and may be the only test needed if the ulcer is acute and very superficial. If the ulcer is chronic or is very deep, samples will be taken for culture and cell study *prior* to applying the stain or other medication.

How is a corneal ulcer treated?

Treatment depends on whether there is a corneal abrasion, corneal ulcer, or descemetocoele present.

Corneal abrasions generally heal within three to five days. Medication is used to prevent bacterial infections (ophthalmic antibiotic drops or ointment), and to relieve spasm and pain (ophthalmic atropine drops or ointment).

"Antibiotic drops are only effective for a short time so they must be applied frequently..."



Antibiotic drops are only effective for a short time so they must be applied frequently; ointments last a bit longer but still require application every few hours. For best results, the antibiotic preparation should be every four to six hours, depending on your pet's condition and acceptance of the medication. On the other hand, atropine generally lasts many hours so this drug is only needed every twelve to forty-eight hours.

If a **corneal ulcer** or a **descemetocoele** is present, steps must be taken to protect the eye and to promote healing. Since dogs do not wear eye patches well, surgery may be required to protect the injury and allow for normal healing. In certain cases, it may be necessary to perform surgery to remove dead or poorly healing layers of corneal tissue (grid keratectomy), or to perform a corneal graft. Your veterinarian will choose the best surgery to optimize healing for your dog.

Can a corneal abrasion progress to become a corneal ulcer or descemetocoele?

Yes. Veterinarians often prescribe broad-spectrum topical antibiotics for simple corneal abrasions or superficial ulcers. In spite of this treatment, the erosion or ulceration can sometimes continue or worsen. Since this can happen and could result in permanent loss of vision, your dog should be re-examined after two to three days to determine if healing is progressing appropriately. If healing is not progressing normally, or if a complication develops, your veterinarian will recommend additional medical treatment or surgery.

Are there any side-effects from the eye medications?

Occasionally a dog will be sensitive to an ophthalmic antibiotic. If your dog seems to be in more pain after the medication is used, discontinue it and contact your veterinarian immediately.

A corneal ulcer is extremely painful so the eye is kept tightly shut. Atropine relieves the pain but also dilates the pupil widely. Therefore, the eye is very sensitive to light and many dogs will squint or close the eye when exposed to bright light. The dilation of the eyes may last for several days after the drug is discontinued.

My dog began to drool excessively and paw at its mouth after I administered the eye medications. Is that a side effect?

No. The tear ducts drain tears from the eyes into the back of the nose where they drain into the throat. Eye medications may drain through the tear ducts and eventually get to the throat where they are tasted.

"Atropine and many other ophthalmic medications have a very bitter taste, which may cause drooling..."

Atropine and many other ophthalmic medications have a very bitter taste, which may cause drooling and pawing at the mouth. You are seeing your dog's response to a bad taste, not a drug reaction.

Since a corneal ulcer is painful, can I apply a topical anesthetic to the cornea?

A topical anesthetic is often used to numb the cornea so the diagnostic tests may be performed. However, these drugs are toxic to the corneal tissues and may delay healing; they are safe for one time use, when used with caution. Atropine is the most commonly used medication to reduce your dog's pain and discomfort due to a corneal ulcer. Some dogs may benefit from the use of non-steroidal anti-inflammatory medications (NSAIDs). Your veterinarian will discuss whether they are safe and appropriate for your pet.

How do I know when to discontinue medication?

The best way to tell that the cornea has healed is to repeat the fluorescein stain test. This will be performed by your veterinarian every one to seven days after treatment has begun, depending on the severity of the lesion and the progress of healing. NEVER discontinue treatment on your own.

There appear to be some red streaks near the ulcer. Is that normal?

There are no blood vessels in the normal cornea. However, when a corneal ulcer or descemetocele occurs, the body will promote healing by forming a new blood supply across the surface of the cornea through a process called *neovascularization*. The new vessels begin at the sclera (the white part of the eye) and cross the cornea to the ulcer.

Neovascularization will speed the healing of the ulcer. The new vessels remain on the cornea once the ulcer has healed; if they are extensive, they will obstruct vision. Therefore, it is desirable to minimize their size. After the ulcer has completely healed, your veterinarian may prescribe drops or ointment containing a corticosteroid for a few days to several weeks, depending on how much neovascularization is present, to reduce the size of the blood vessels.

It is important that corticosteroids (steroids) are not used in the eye too soon because they will slow or stop the healing process and may cause serious complications. Your veterinarian will repeat the fluorescein dye test BEFORE beginning this type of medication. If steroids are used and the eye becomes painful again, immediately discontinue the steroids and have the eye rechecked by your veterinarian.

*This client information sheet is based on material written by: Ernest Ward, DVM
© Copyright 2009 Lifelearn Inc. Used and/or modified with permission under license.*